

Unusual delayed presentation of Bochdalek Hernia in children: Report of two cases

Gowthami Adusumilli, Raghavendra Vanaki, Ramesh Pol, Bhuvanewari C. Yelamali, Ashok Badakali

Department of Paediatrics, S. N. Medical College & HSK Hospital, Bagalkot, Karnataka, India

Abstract

Background: Bochdalek hernia was first described by Czechoslovakian anatomist, Vincent Alexander Bochdalek. It is a life threatening condition with high mortality if presented in the neonatal period. Rarely, the presentation may be delayed, in which case symptomatology is different and with timely surgical intervention, prognosis is excellent. We present two cases of left Bochdalek hernia with delayed presentation in view of its rarity and pitfalls in diagnosis due to misleading symptomatology.

Case reports: Case 1: 2 year old male child presented with complaints of fever of low to moderate grade and dry, non-productive cough of ten days duration. Examination of respiratory system revealed bilaterally symmetrical chest with decreased movements on left side. Breath sounds were decreased in left infrascapular, interscapular and infraaxillary regions. Chest X-ray showed congenital diaphragmatic hernia. CT scan chest, abdomen and pelvis revealed congenital diaphragmatic hernia (Bochdalek Hernia). **Case 2:** 1 year male child presented with history of chest retractions and on and off episodes of fever, cough, hurried breathing since 2 months of life with examination findings of severe acute malnutrition, tachypnea, retractions, absent air entry on left axillary and infrascapular areas with coarse crepitations. Chest x-ray showed congenital diaphragmatic hernia. Both children underwent laparoscopic repair of diaphragmatic defect and discharged safely.

Conclusion: Congenital diaphragmatic hernias are uncommon diagnosis among children due to its rarity and variable clinical features. Possibility of Bochdalek hernia with delayed presentation should always be kept in differential diagnosis of a child presenting with recurrent episodes of pneumonia or persistent respiratory signs and symptoms.

Key words: Late onset, Bochdalek, diaphragmatic hernia.

Introduction

Bochdalek hernia is a posterior congenital defect caused by lack of closure of pleura-peritoneal cavity between 8th and 10th week of embryonic life. Between 70%-90% of cases occur on left side^[1]. It was first described by Czechoslovakian anatomist, Vincent Alexander Bochdalek^[2]. It is a life threatening condition with high mortality if presented in the neonatal period and not managed appropriately. Rarely, the presentation may be delayed, in which case symptomatology is different and with timely surgical intervention, prognosis is excellent^[3]. We present cases of left Bochdalek hernia with delayed presentation in view of its rarity and pitfalls in diagnosis due to misleading symptomatology.

Case Reports

Case 1: A 2 year old male child presented with complaints of fever of low to moderate grade and dry, non-productive cough of ten days duration. Examination revealed child weighing 10 kg with normal vital parameters. Examination of respiratory system revealed bilaterally symmetrical chest with decreased movements on left side. Breath sounds decreased in left infrascapular, interscapular and infraaxillary regions. Other systems were essentially normal. Investigations revealed normal haemoglobin, blood count ESR, mantoux and sputum for AFB were negative. Chest X-ray revealed left hemidiaphragm higher than right with loss of continuity of border of left hemidiaphragm, with collapse of left lower lobe

Corresponding author

Dr. Raghavendra Vanaki

Department of Pediatrics, S. N. Medical College & HSK Hospital, Bagalkot, Karnataka, India

E-mail: raghuvanaki@yahoo.co.in

with bowel loops extending into left hemithorax which were signs of congenital diaphragmatic hernia (Figure 1). CT scan chest, abdomen and pelvis showed herniation of a part of stomach, spleen, splenic flexure and part of transverse and descending colon through defect in diaphragm in left postero-lateral aspect - Congenital diaphragmatic hernia (Bochdalek Hernia, figure 3)

Case 2: 1 year male child with history of retraction and on and off episodes of fever, cough, hurried breathing since 2 months of life with examination findings of severe acute malnutrition, tachypnea, retractions, absent air entry on left axillary and infrascapular areas with coarse crepitations. Hemoglobin was 10gm%, elevated total counts with neutrophilia; Chest X-ray revealed left hemidiaphragm higher than right with loss of continuity of border of left hemidiaphragm, with collapse of left lower lobe with bowel loops extending into left hemithorax showing signs of congenital diaphragmatic hernia (Figure 2).

Both children underwent laparoscopic repair of diaphragmatic defect and discharged safely.

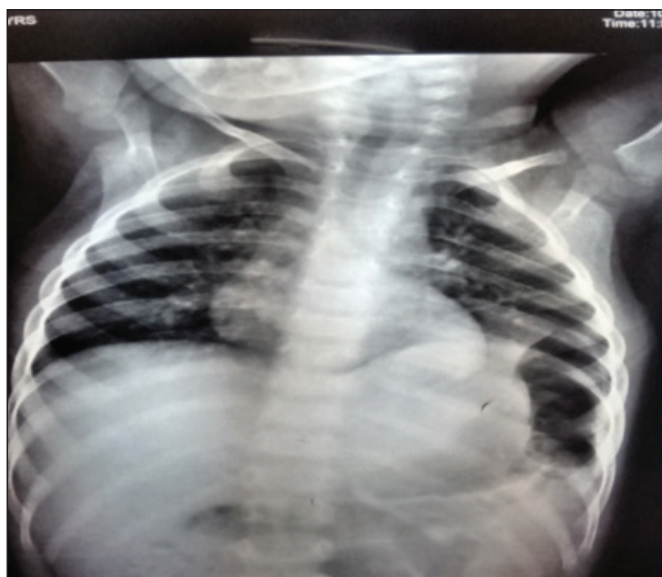

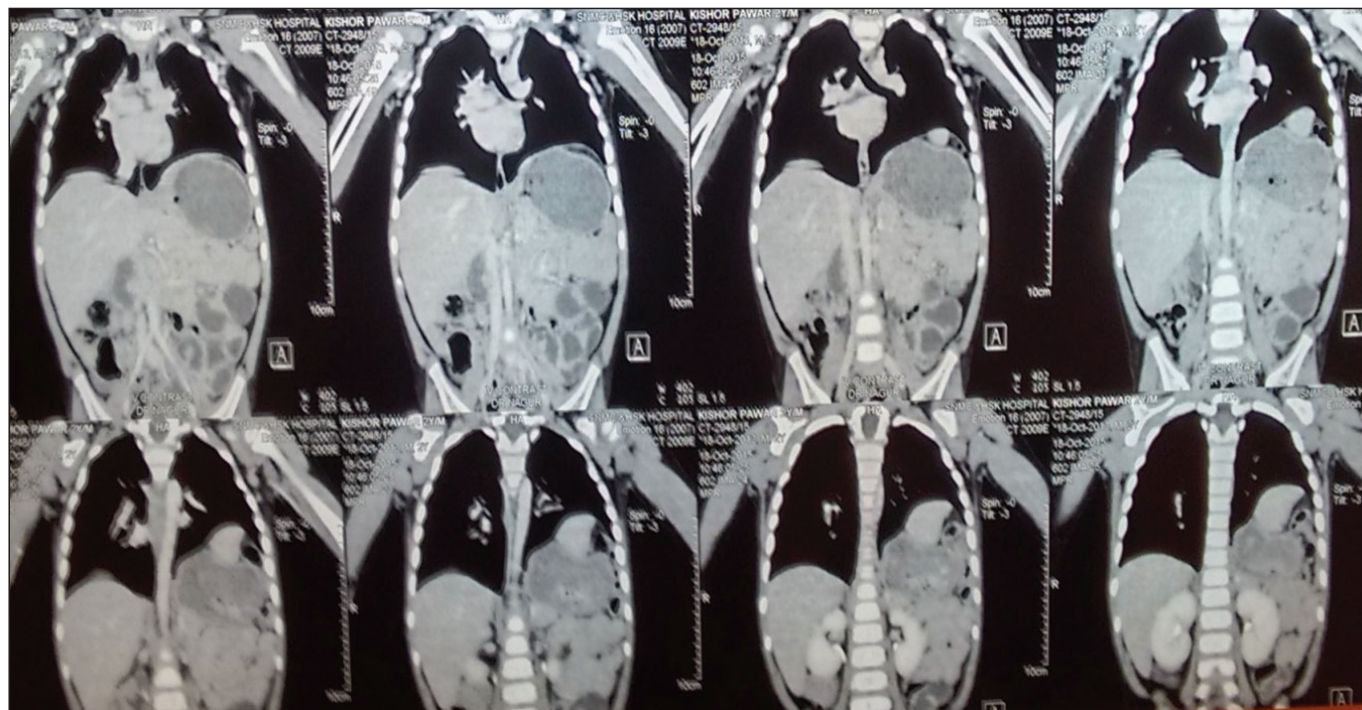
Figure 1. Chest X-ray of case 1

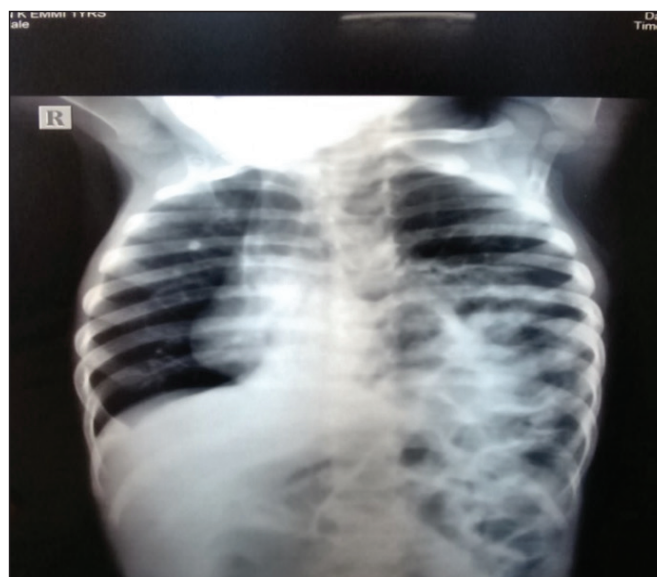

Figure 2. Chest X-ray of case 2

Discussion

Embryologically, the diaphragm develops by the fusion of various components during ninth week of intrauterine life. The right hemidiaphragm completes its closure before the left. Last area to close on either side is the postero-lateral portion known as foramen of Bochdalek. Bochdalek hernia is caused by lack of closure of pleuroperitoneal cavity by incomplete diaphragmatic development before intestines return to the abdomen between 8 to 10 weeks of gestation. The occurrence rate is 1 in 7000 live birth, of which presentation is delayed in 5-10% of patients. There is male preponderance with male to female ratio of 2:1^[4]. If hernia formation precedes lung development pulmonary hypoplasia may occur with severe respiratory compromise at birth. If newborns does not become symptomatic within 8 hours after birth, symptoms that appear late are probably due to simple lung compression^[5,6]. Late presentation poses diagnostic difficulty because of its rarity and misleading clinical features. These children remain asymptomatic for months to years and are picked up often incidentally when chest x-ray is done for some other purpose. They usually present with gastrointestinal as well as respiratory symptoms^[6]. Respiratory symptoms are chronic or recurrent but less severe than in newborn, may be due to good respiratory compensatory mechanism. The difference in symptoms may delay correct diagnosis^[7]. X-ray in such cases is diagnostic and at times upper gastrointestinal contrast studies may be resorted to confirm diagnosis. The definitive treatment is surgery and needs thoracotomy /laprotomy and repair of

Figure 3. CT scan of case 1 showing herniation of stomach and spleen into thorax

defect in the diaphragm. The postoperative recovery and longterm outcome depends upon developmental status of the lung. In delayed presentation the lungs are usually mature and longterm outcome is excellent. Chest physiotherapy enhances the speed of recovery.

Both of our patients had a left congenital diaphragmatic hernia which was detected when chest x-ray is taken for respiratory symptoms. Diagnosis is confirmed by CT scan chest and abdomen in one child. Defect is corrected by laparoscopic closure. Both patients remained symptom free during period of follow-up.

Conclusion

Congenital diaphragmatic hernias are uncommon diagnosis among children due to its rarity and variable clinical features. Possibility of Bochdalek hernia with delayed presentation should always be kept in differential diagnosis of a child presenting with recurrent episodes of pneumonia or persistent respiratory signs and symptoms.

References

1. Perch P, Houch W, de Anda A. Symptomatic Bochdalek hernia in an octogenarian. *Ann Thorac Surg* 2002;73:1288-9.
2. Puri P, Wester T. Historical aspects of congenital diaphragmatic hernia. *Pediatr Surg Int* 1977;12:95-100.
3. Vukic Z. Left Bochdalek hernia with delayed presentation: report of two cases. *CMJ* 2001;42(5):569-71.
4. Graivier L, Dorman GW, Votteler TP. Congenital diaphragmatic hernia in children. *Surg Gynecol Obstet* 1971;132(3):408-10.

5. Alagappan A, Malloy MH. Outcome of congenital diaphragmatic hernia: ten years experience after ECMO. *Pediatrics* 1997;10(2):517-8.
6. Osebold WR, Soper RT. Congenital diaphragmatic hernia past infancy. *Am J Surg* 1976;131:748-54.
7. Kirkland JA. Congenital postero-lateral diaphragmatic hernia in the adult. *Br J Surg* 1959;47:16.

Conflict of interest: Nil

Source of funding: Nil

Date received: June 5th 2017

Date accepted: July 15th 2017